

A post-extractive implant case with a CAD/CAM solution on a zirconia collar tissue-level implant

# Benefits of an immediate tissue-level implant protocol

DR RÉGIS NÈGRE, RODEZ, FRANCE

The main challenge with post-extraction implant cases is the preservation of native bone. It's important to maintain as much of the bone as possible, in order to ensure that the implant has sufficient primary stability. The immediate implant placement protocol further helps to preserve the natural bone volume [1,2]. Delayed implant placement protocols require a waiting time of three to four months after the extraction for bone healing before implant placement. During this time, the patient can lose a significant amount of bone height and width [3–5] if no bone regeneration is performed. The immediately placed implant has a “tent” effect, supporting soft tissue volume [6] to encourage regeneration where necessary, and leading to higher implant stability compared to conventional implant placement techniques [7].

The protocol carried out and the material used in this case allowed the restoration of the patient's smile in just two stages: a surgical one and a prosthetic one. The approach with only two steps offers several benefits. The patient only needs to attend one 40-minute appointment for extraction and implant placement, and a second 40- to 50-minute appointment for impressions and the manufacture and fitting of the CAD/CAM restoration.

## Case presentation

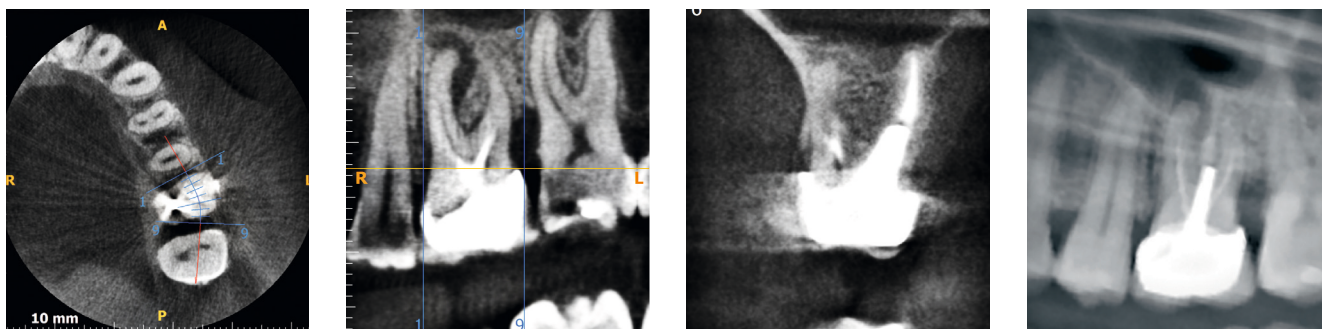
A 35-year-old female patient presented with a previously restored molar that

was causing problems. Upon X-ray, a very long post was identified in the existing crown, as was an apical lesion (Figs. 1 and 2). This gave the molar a hopeless prognosis and extraction was therefore indicated. The option of extraction with immediate implant placement was discussed and agreed on with the patient.

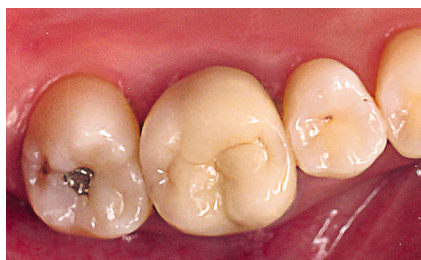During the first appointment, the crown and the post were removed (Fig. 3). The three remaining roots were separated in order to perform the most atraumatic extraction possible (Figs. 4 to 6). It has been suggested that this helps to preserve the interradicular bone (Fig. 7)

and facilitates primary stability of the implant when placed [8,9]. The roots were then extracted and the socket cleaned in order to remove any infection.

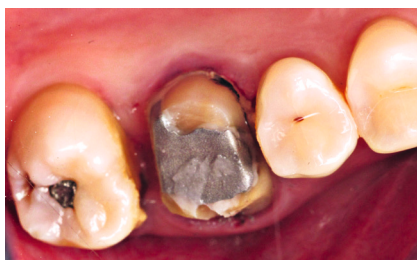The pilot drill was used to mark the entry point of the implant in the bone, located in the centre of the remaining interradicular bone (Figs. 8a and b). A 5 mm diameter tissue level dental implant with a 6 mm diameter platform and 2.5 mm height zirconia collar (Z1; TBR, Toulouse, France) was placed (Fig. 9), followed by the cover screw (Fig. 10). Almost all of the recommended drilling sequence was used – preparation stopped short of the



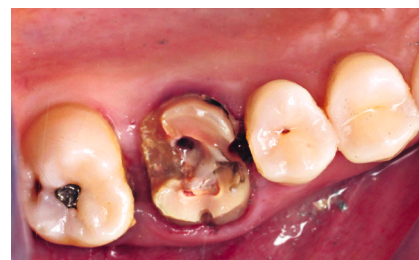1 | Radiograph demonstrating long crown post and apical infection.



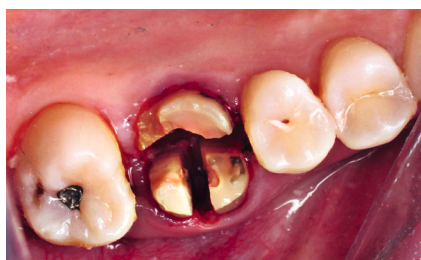2 | Intraoral view before treatment.



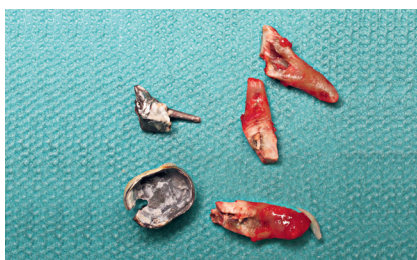3 | Crown removal.



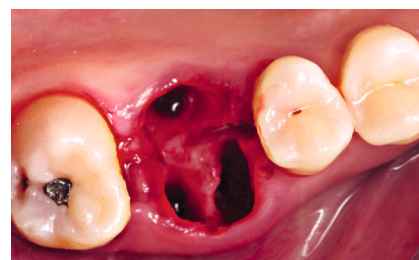
4 | Inlay core removal.



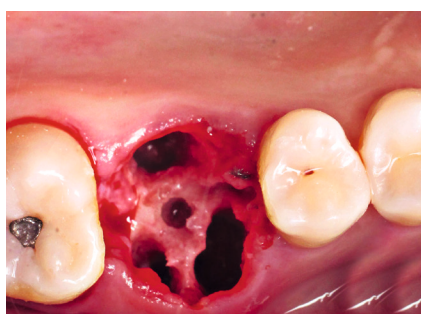5 | The roots are separated to allow for a more atraumatic extraction.



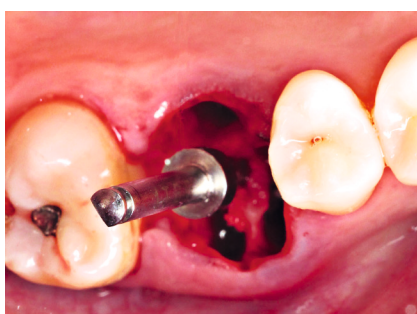
6 | The extracted roots.



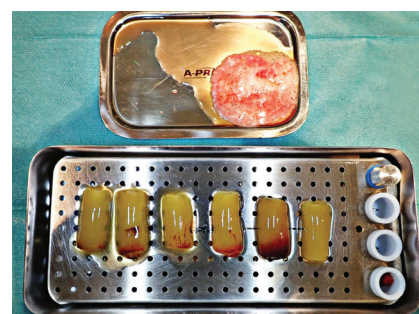
7 | Preservation of the interradicular bone.



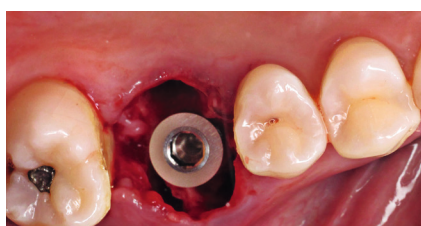
8a | Drilling...



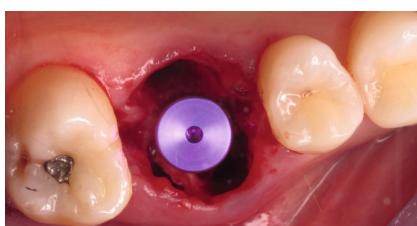
8 b | ... and preparation of the socket.



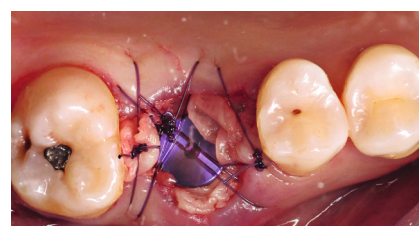
9 | Preparation of the PRF and allogeneic graft material.



10 | Immediate placement of the Z1 implant (TBR) under the cemento-enamel junction of the adjacent teeth.



11 | Cover screw placed.



12 | Grafting material placed and wounds sutured.

final drill in order to under-prepare the soft bone for higher primary stability. In position 26, we often deal with D3 or D4 bone, making the design of the implant threads of vital importance for the outcome of the restoration.

The efficient threads of the tissue-level implant promote stability, encouraging success even in high risk or limited bone situations. Another benefit of this surgical technique is that the clinician can decide on the most suitable depth

of the implant and thus the position of the zirconia collar in contact with the soft tissue.

From 15 years of experience with this technique, the author has learned that placing the zirconia collar 1 mm beneath the cemento-enamel level on both the palatal and buccal aspects, leads to improved aesthetics. According to *Dr Joseph Choukroun's* protocol [10], I-PRF (Injectable Platelet-Rich Fibrin) and an allogeneic bone grafting material were placed

to improve bone quality, quantity and healing (Figs. 11a and b). An A-PRF (Advanced Platelet-Rich Fibrin) membrane was placed over the top to protect the bone graft and implant. The wound was then closed with O-shaped sutures, being sure not to create any tension in the soft tissue so as to prevent bone resorption (Fig. 12). The patient was prescribed antibiotics, anti-inflammatories and painkillers to aid comfort and healing.

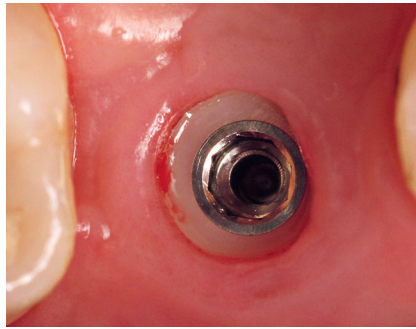
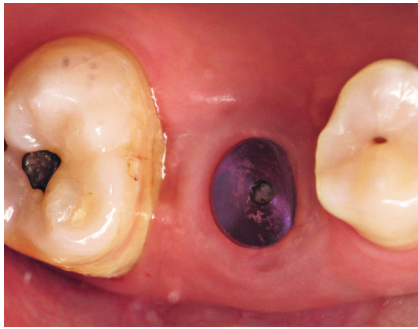

**Follow-up**

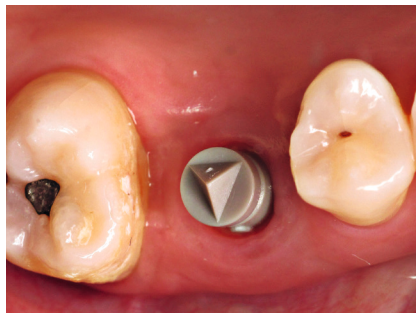
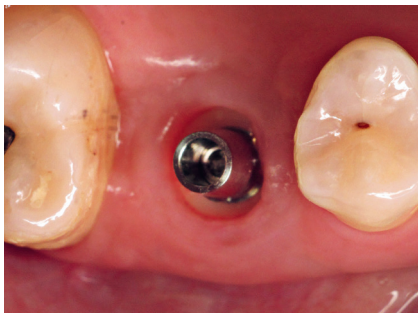
Four months later the patient returned for her follow-up appointment. The X-ray demonstrated no bone loss and perfect osseointegration of the implant within the surrounding bone. Ideal healing of the soft tissue around the zirconia

collar could be seen and the zirconia collar had integrated well with both the bone and gingiva to produce a very good emergence profile (Fig. 13). This made restoration simpler through CAD/CAM protocols, as a titanium base and scan-body could be placed onto the zirconia

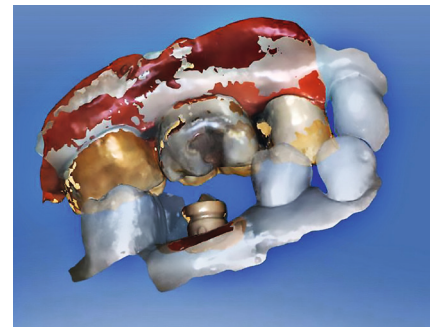
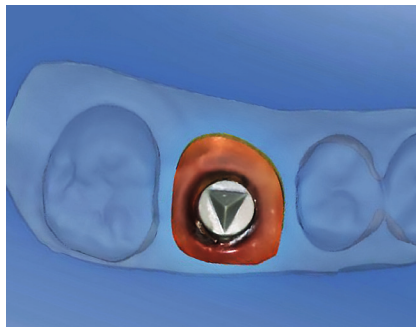
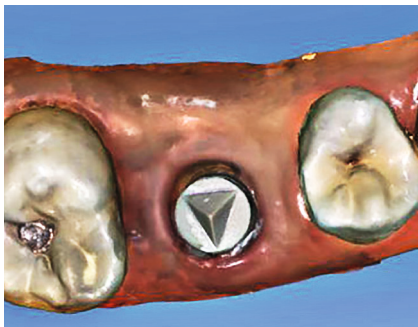
platform in order to take a digital impression (Figs. 14 to 17). The use of a chair-side CAD/CAM workflow made treatment quicker – the restoration could be designed, manufactured and placed in a single appointment – more accurate and more comfortable for the patient.



13 | Four months post surgery.  
14 | Cover-screw removed.



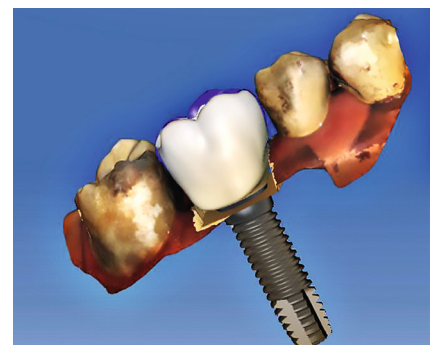
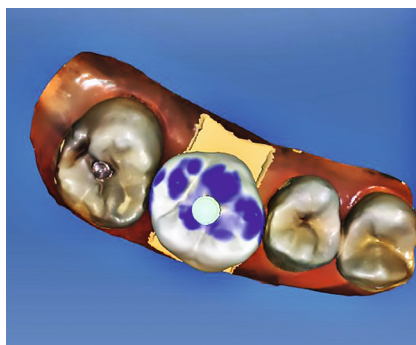
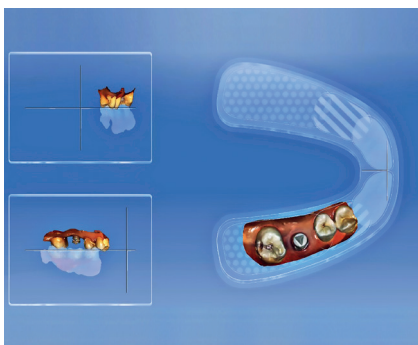
15 | Titanium base ...  
16 | ... and scan body placed.



17 | Digital impression.

18 | The work area is reduced with the software.


19a | Virtual articulator ...



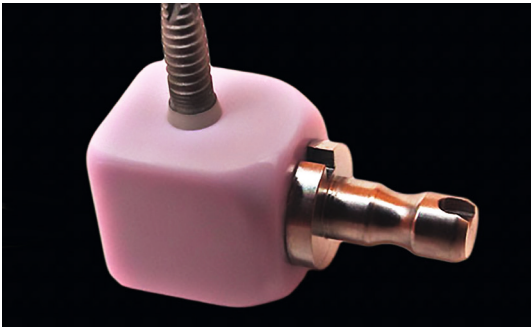
19b | ... used to check occlusion.

20a | Implant position ...

20b | ... and crown are designed digitally.



21 | Pre-drilled e.max block.

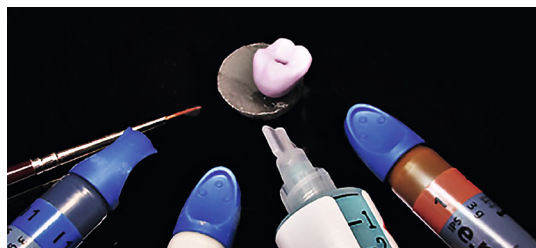


22 | Precision fit with the Z1 implant.

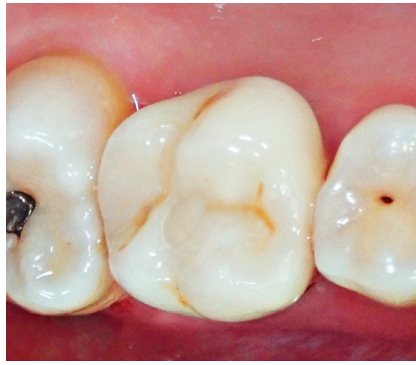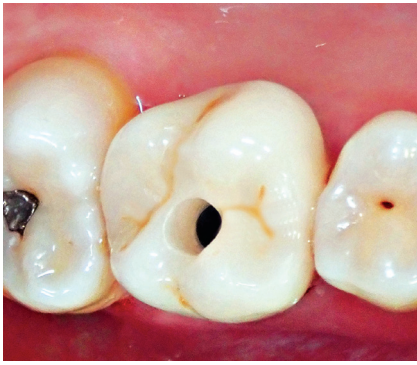


23 | The crown is milled ...

24 | ... and finished.

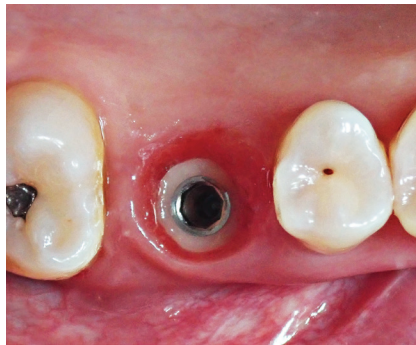
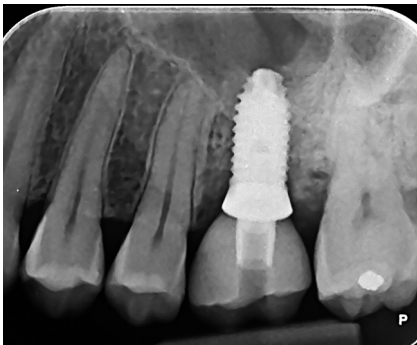


Using digital design software, the work area was reduced to the immediate region of the implant (Fig. 18), while both arches were put into the virtual articulator to check occlusion (Figs. 19a and b). The restorative design was performed on the virtual implant (Figs. 20a and b). The software is very intuitive and automatically recognizes the type of implant solution used. The restoration was then fabricated from an IPS e.max bloc (Ivoclar Vivadent, Schaan, Liechtenstein) and the final touches were made (Figs. 21 to 24).



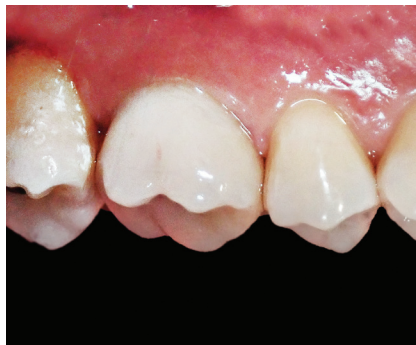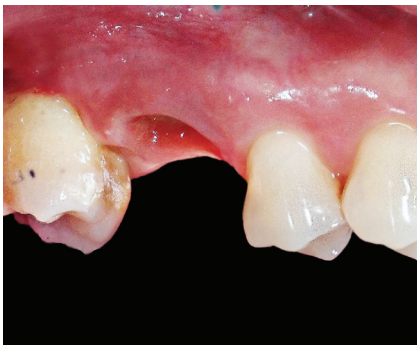25 | Screw-retained crown in the patient's mouth.

26 | The screw-hole is filled with composite.



27 | Post-treatment radiograph.

28 | Creeping attachment of gingiva after six months of crown placement.



29 | Papilla repositioning ...

30 | ... and final restoration after six months of crown placement.

The comparison between a tissue level surgical technique versus a bone level surgical technique shows a considerable advantage. In this case, the CAD/CAM-fabricated crown is fixed directly on the implant platform. However, if we had to opt for a bone level surgical technique, this same crown would have been cemented onto the shoulder of an abutment. The selected surgical technique is therefore much less invasive for soft tissues. On the one hand, it does not constrain or mobilize the gingival tissues once the implant has been placed, and on the other hand, zirconia has aesthetic and antibacterial properties superior to titanium. In this technique, the combination of using a zirconia collar at soft tissue level and a CAD/CAM-fabricated crown ensures a ceramo-ceramic con-

tinuity, significantly improving the aesthetics of the restoration.

The final restoration was screwed into place with a torque of 30 Ncm (Fig. 25). Composite was placed to fill the screw access hole and complete the occlusal surface of the crown (Fig. 26). Figure 27 shows the post-treatment radiograph, Figures 28 to 30 demonstrate papilla formation and creeping attachment along the emergence profile after six months of crown placement.

#### Discussion

A wider platform implant was used in this case, as this was appropriate for restoring a molar tooth. It creates a more natural-looking soft tissue emergence profile and this in turn makes oral hygiene easier to achieve for the patient in the long-term.

The author only uses a zirconia collar height of 2.5 mm, as this is the ideal size to ensure that it remains 1 mm below the periodontal tissue. The zirconia collar provides a natural barrier to infections as the gingiva adheres to it, protecting the implant, the bone, the gum and therefore, the overall restoration [11]. All of this together ensures the long-term stability and survival of the dental implant. ■

The references are available at [www.teamwork-media.de/literatur](http://www.teamwork-media.de/literatur)

#### Contact address

Dr Régis Nègre  
8, rue Planard  
12000 Rodez  
France  
[docteur.negre@free.fr](mailto:docteur.negre@free.fr)

