

## Clinical

# TBR Z1 implants with guided surgery and immediate loading to manage lateral incisor agenesis

**Carlos Barrado** and **Juan Ambros** detail an implant case where immediate loading and tissue-level implants were used together for an enhanced aesthetic outcome

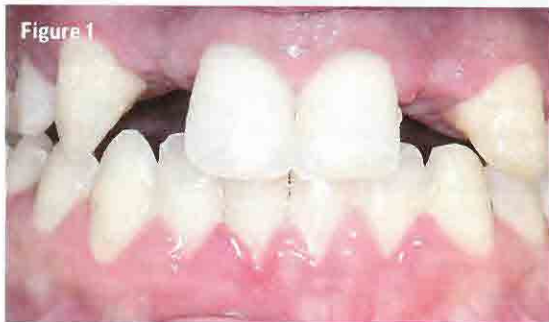

Figure 1



Figure 2

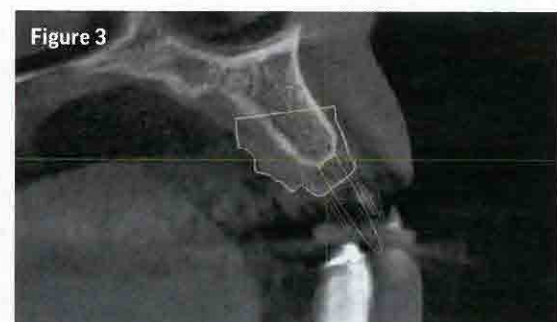


Figure 3

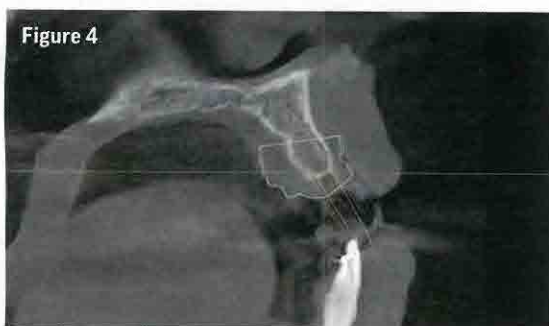


Figure 4

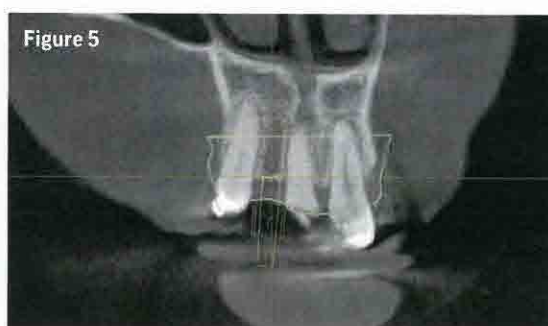


Figure 5

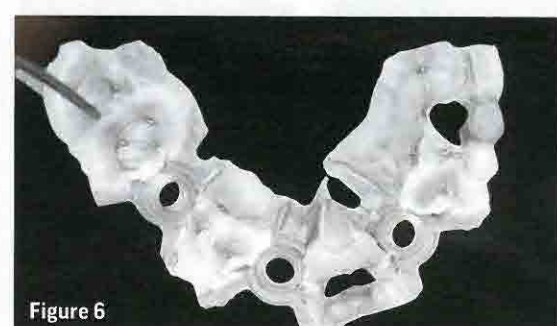

Figure 6

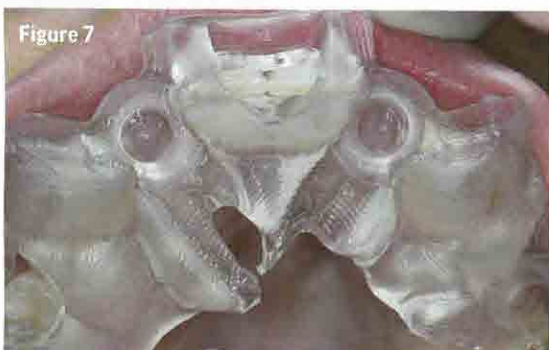

Figure 7

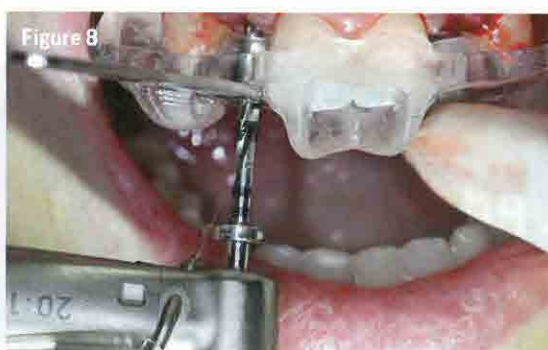

Figure 8

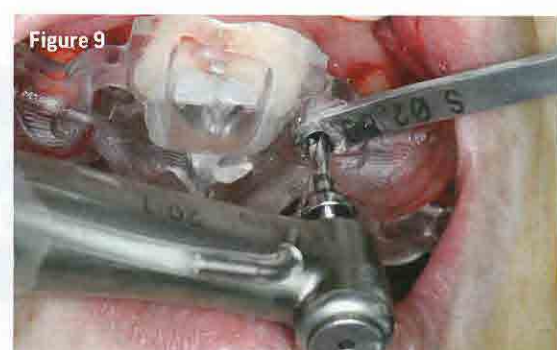

Figure 9

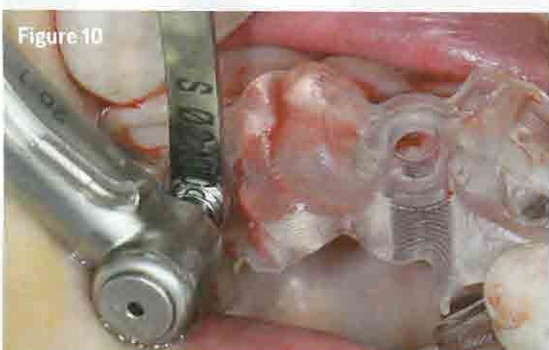


Figure 10

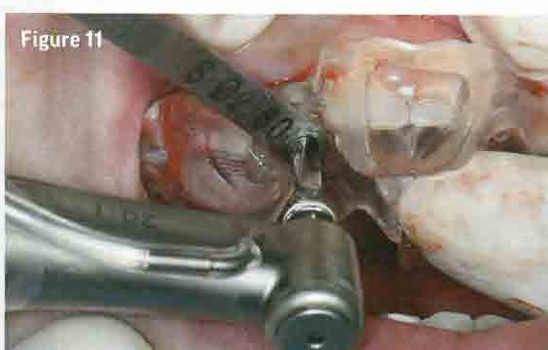


Figure 11

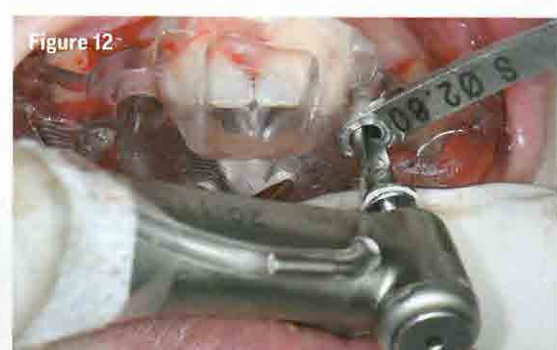

Figure 12

A 22-year-old female patient, who was affected with maxillary lateral incisor agenesis, presented to the practice looking for a solution to the gaps in her anterior teeth (Figure 1). She had recently completed orthodontic treatment, which allowed any restorative dentistry to proceed. Other than some minor hygiene issues on her lower teeth, the patient was in good oral health, making her an acceptable candidate for implant treatment.

During the patient's orthodontic treatment, she had been given temporary crowns to hide the gaps in her teeth, but she was eager to receive a non-removable solution. The proposed treatment was explained to her and she gave

informed consent, allowing the procedure to move forward.

After radiographic assessment it was discovered that, due to the position of the surrounding teeth, it would be necessary to undertake guided surgery in this case. The placement sites for the proposed implants were very restrictive – making accuracy a particularly important consideration. Without the ability to digitally plan for guided surgery, implants would not have been a viable option.

## Treatment planning

Extensive planning was undertaken, utilising both CBCT scans and traditional X-rays (Figures 2-5). The position

of the implants was very carefully considered due to the restrictions of the placement sites and a surgical guide was manufactured to facilitate surgery (Figure 6).

After this prolonged planning period, the patient came back to the practice for surgery and implant placement. To ensure a good aesthetic result, the implants were immediately loaded to help maintain the soft tissue and increase papillae volume going forward. To this end, we decided that the flapless technique would be the best way of enhancing the soft tissue result and enabling a minimally invasive procedure.

The TBR Z1 implant was the system of choice for this ▶

## Clinical

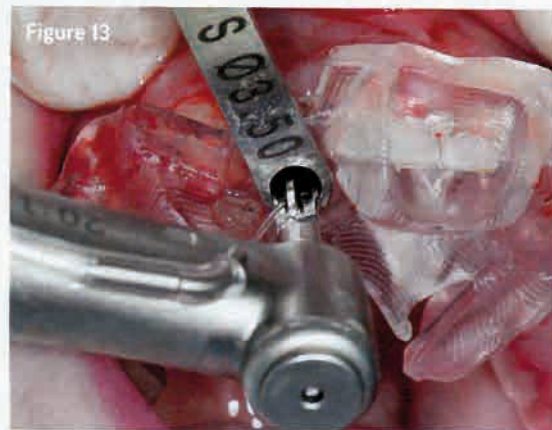


Figure 13



Figure 14

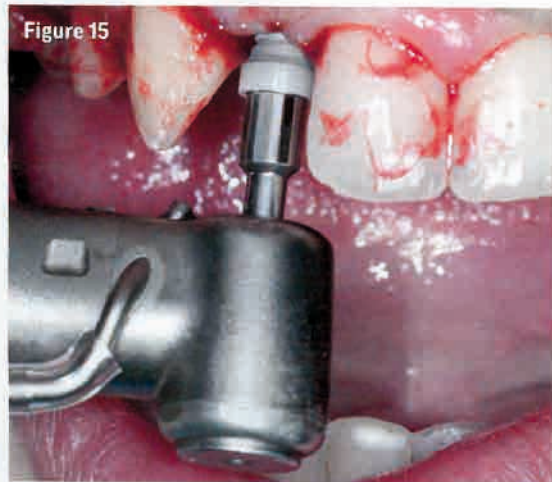

Figure 15

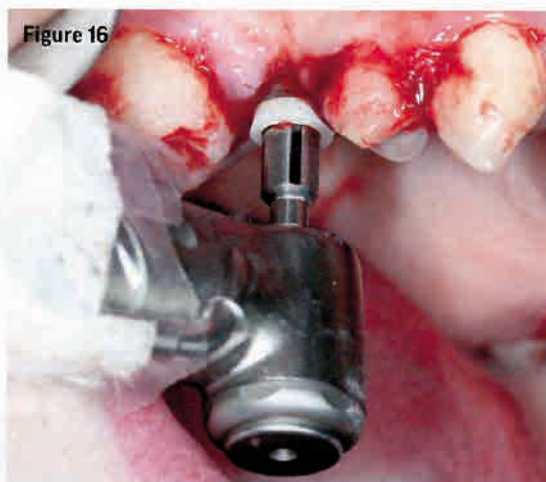

Figure 16

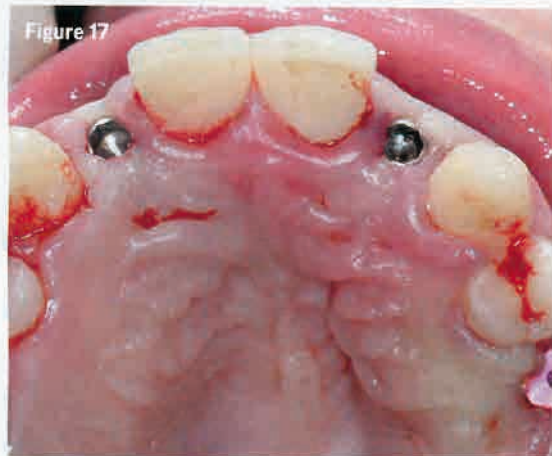

Figure 17

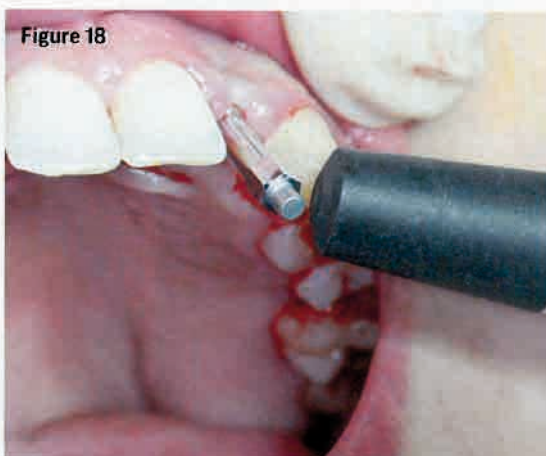


Figure 18

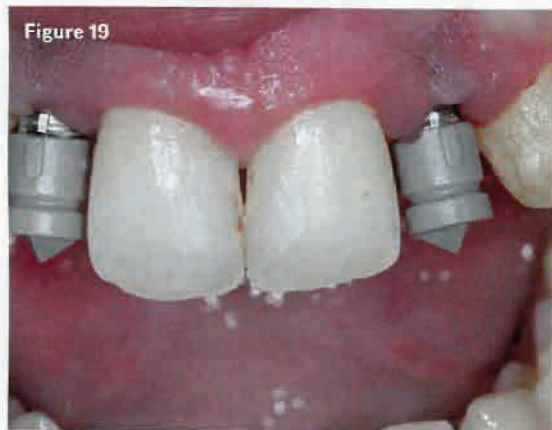

Figure 19

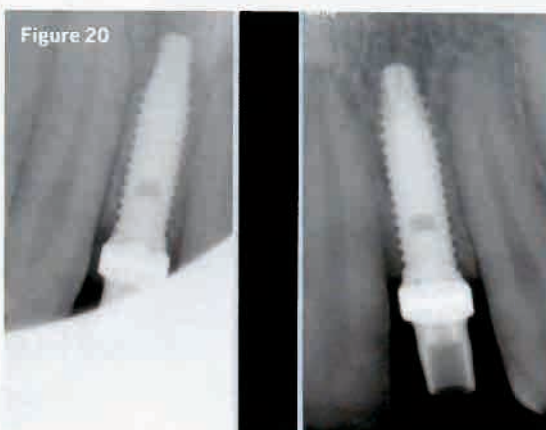


Figure 20

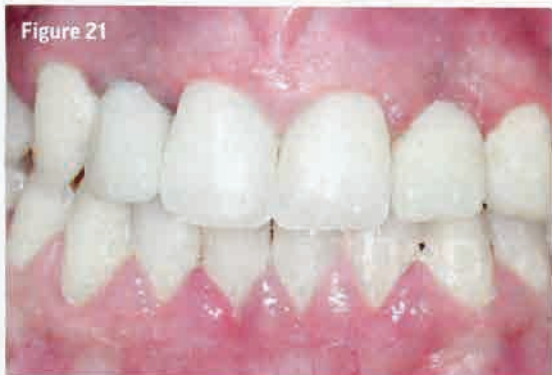

Figure 21

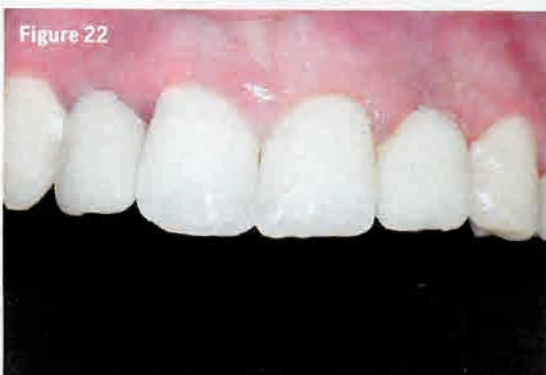

Figure 22

case, due to its aesthetic advantages in the anterior region and its very strong primary stability. TBR also provides the tools for advanced digital implant planning with the Z1, which was essential in this complicated case.

### Implant placement

Surgery took only 15 minutes to complete and there were no issues thanks to the level of planning that had taken place before the procedure commenced (Figures 8-18).

Once placed, the TBR Tibases were screwed on the implants and Sirona scan bodies were set upon the Tibases (Figure 19). Once these were in situ, an X-ray was taken to ensure a successful placement (Figure 20) and a digital impression was taken and sent to the laboratory. We are lucky enough to have a laboratory situated with our practice, which means that the manufacturing

**To ensure a good aesthetic result, the implants were immediately loaded to help maintain the soft tissue and increase papillae volume**

process for any restoration can be accomplished very quickly. In this case, the patient only had to wait an hour before her temporary crowns were ready to be fitted. This level of teamwork helps improve our treatment outcomes significantly and ensures patients receive exceptional results.

The temporary crowns were fitted and the patient could leave with a customised fixed solution on the same day (Figures 21 and 22).

### Discussion

From the very beginning, it was recognised that during the osseointegration period this would be an aesthetic restoration, not a functional one, since the teeth to be restored were out of occlusion. As it happens, treatment was conducted and completed on the patient's birthday – and she could not help but cry with happiness at the result: the perfect birthday present!

In this case, immediate loading helped enhance the soft tissue management and the zirconia soft tissue collar of the Z1 implant also helped increase the volume of the papillae.

After three months of healing, the soft tissue volume around the implants will have increased enough for a truly exceptional aesthetic result. Indeed, the purpose of immediate loading is to manage the soft tissue and effectively preserve the papillae.

Thanks to the combination of the Z1 implant, the use of immediate loading and guided flapless surgery, the papillae were preserved and enhanced for a better aesthetic result.

The Z1 tissue-level implants were used in this case to great effect; they were preferred to other implant systems here due to the ease with which digital techniques can be incorporated into the procedure to facilitate true guided surgery and the final CAD/CAM prostheses. The zirconia collar of the Z1 was also instrumental in ensuring a good aesthetic result in the anterior region. **D**



Dr Juan Ambros gained his bachelor of medicine and surgery in 1980 and became a specialist in stomatology in 1983. He is a renowned international professor, trainer, and lecturer in his field.



Dr Carlos Barrado has been the medical director of his own dental clinic since 1990. He has a degree in implant dentistry, an MSc in periodontics and implant dentistry and another in implant dentistry. He is a teacher in the Medical Implant System training team.