

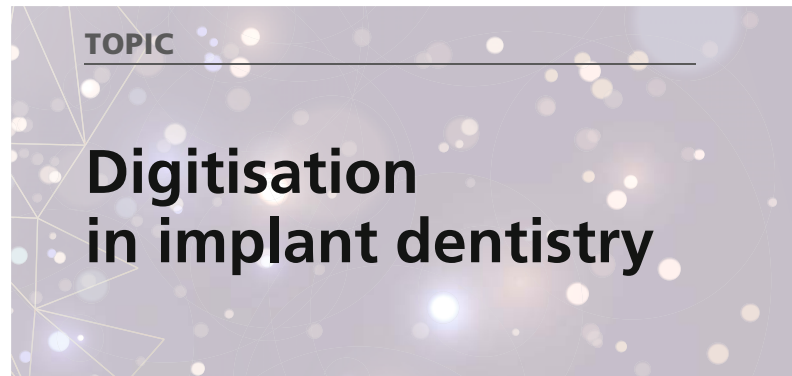





EDI Journal

European Journal for Dental Implantologists



»EDI News: Coming up: 18th Expert Symposium in Cologne in February 2023—Update on short, angulated and reduced-diameter implants · BDIZ EDI general meeting—association with sound prospects · Update implantology—seminar offers online in 2023
»Case Studies: Digital support for simulating bite alterations in the periodontally compromised dentition · Treatment of a case of atrophic-erosive lichen planus refractory to topical corticosteroid with endoret-PRGF and rehabilitation with dental implants



A case series with one-year follow-up

Immediate placement of titanium implants with a zirconia neck in the aesthetic zone

Drs Simone Marconcini , Enrica Giammarinaro, Giovanni-Battista Menchini Fabris & Ugo Covani, Italy

Introduction

In the case of single edentulism, the use of dental implants is a wise treatment choice, as under the same anatomical conditions, it safeguards the adjacent teeth.¹⁻³ A single implant is also a cost-effective option in comparison with a traditional three-unit fixed dental prosthesis.⁴ Furthermore, implant dentistry has progressed towards simplifying clinical protocols and reducing surgical entries, having immediate implant placement and immediate implant provisionalisation as treatment options.^{5, 6}

However, despite the continuous improvement of implant materials and surgical techniques, achieving a good aesthetic outcome is often challenging.⁷ Sometimes, especially when using a transgingival implant design, it is difficult to manage titanium translucency through the cervical mucosa, and this inconvenience is more frequent in patients with a thin gingival

biotype.⁸ Once the prosthesis has been delivered, augmenting the thickness of the soft tissue by means of coronally advanced flaps or free connective tissue grafts is an option, but the additional surgery is not always accepted by patients.⁹

Zirconia implants have been recommended for highly demanding aesthetic situations primarily involving the anterior maxillary zone.¹⁰ Zirconia has shown great success at maintaining marginal soft-tissue stability around fixed dental prostheses,¹¹ and it has been associated with connective tissue stability and increased fibroblast collagen production in histological studies.¹² Still, zirconia implants' physical characteristics, including lower fracture resistance, compared with those of titanium have limited their use to patients with good occlusal stability.¹³

One-piece titanium implants with a zirconia collar have been developed, and they have been associated with strong fibroblast and osteoblast adhesion and inhibition of bacterial prolife-

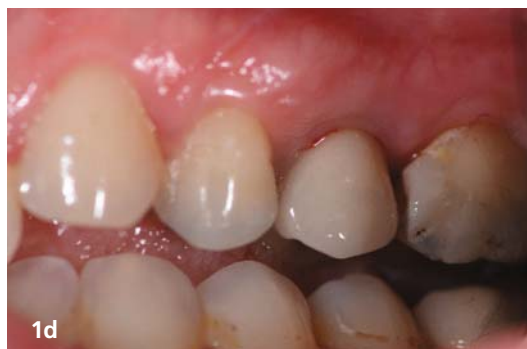
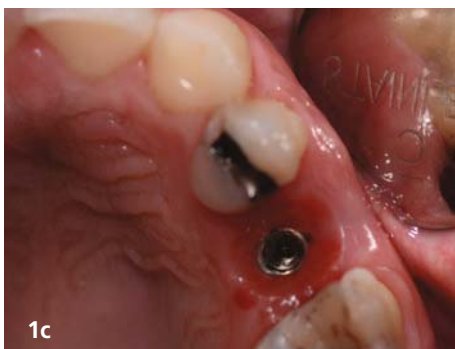
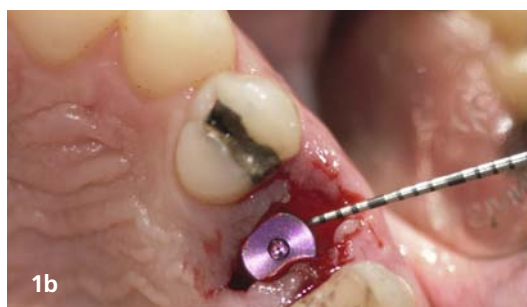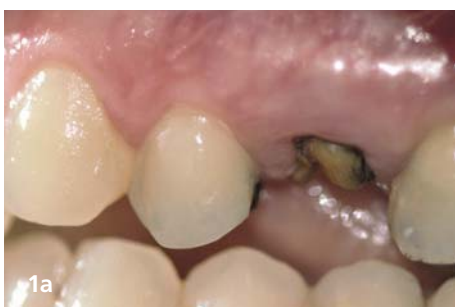Fig. 1a: This 45-year-old female patient presented with a fractured maxillary second premolar. **Fig. 1b:** A Z1 Infinity implant (TBR Dental) was placed immediately following the palatal slope of the extraction socket. **Fig. 1c:** Four months after implant placement, the tissue around the provisional prosthesis appeared healthy. **Fig. 1d:** The buccal appearance of the peri-implant tissue disguised the presence of an implant. No implant radiolucency was detectable.

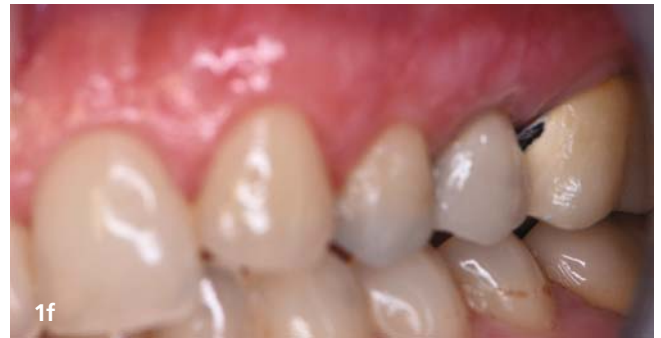
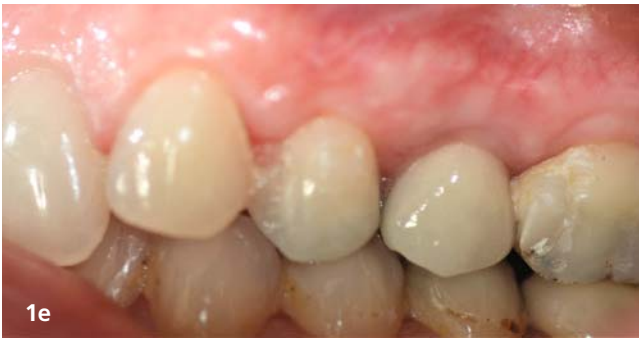
Fig. 1e: The definitive prosthesis was delivered four months after surgery. **Fig. 1f:** The peri-implant mucosa was healthy and stable at the five-year follow-up.

ration.¹⁴ The intimate connection at the interface between the two materials allows the implant to behave like a single body, preventing deformation, compression or torsion.^{15, 16} The aim of the present case series study was to evaluate the survival and success rate of a titanium implant featuring a 1.5 mm zirconia neck, giving special attention to the aesthetic results in the anterior zone. The Z1 Infinity implant (TBR Dental) combines two materials adapted to the tissue with which they are in contact—titanium to the bone and zirconia to the mucosa—with the aim of enhancing periodontal stability around the implant.

Materials and methods

Patient selection

The present case series study complies with the principles stated in the World Medical Association (WMA) Declaration of Helsinki, as adopted by the 18th WMA general assembly in Helsinki in Finland in June 1964 and as amended most recently by the 64th WMA general assembly in Fortaleza in Brazil in October 2013.

The study population included ten patients requiring single-tooth extraction and immediate implant placement, six women and four men, ranging from 28 to 65 years old. All participants provided written informed consent. During treatment planning, each case was accurately evaluated by examining diagnostic casts for the inter-arch relationship and examining periapical and panoramic radiographs and CT scans, if needed.

The inclusion criteria for patient selection were as follows:

1. good general health and no history of systemic disease;
2. fair occlusal stability (> 20 teeth);
3. need for implant surgery in the aesthetic zone.

The exclusion criteria were as follows:

1. smoking more than ten cigarettes per day;
2. having received radiotherapy to the head or neck area;
3. severe systemic conditions impairing bone healing;
4. dehiscence or fenestration in the residual bony walls;
5. acute infection at the surgical site;
6. alcohol or drug abuse; and
7. oral parafunctional habits.

Preoperative procedure

All patients, prior to the experimental procedure, underwent a complete periodontal evaluation. With the aid of a #15 UNC periodontal probe, probing pocket depth, clinical attachment level, full-mouth plaque score and full-mouth bleeding score were assessed. Thereafter, patients were instructed on improving selfperformed oral hygiene and enrolled in a professional maintenance programme. Experimental intervention was postponed until patients showed proper periodontal tissue stability.

On the day of the experimental procedure, a prophylactic systemic antibiotic regimen (2 g amoxicillin and clavulanic acid) was started 2 hours before surgery. Immediately before the surgery, patients were rinsed with ozonised water for 1-minute intervals.

Surgical procedure

All patients were treated by a single surgeon. The implants were immediately inserted after tooth extraction. Local anaesthesia (Optocain 20 mg/ml, Molteni Dental; adrenaline 12.5 µg/ml)

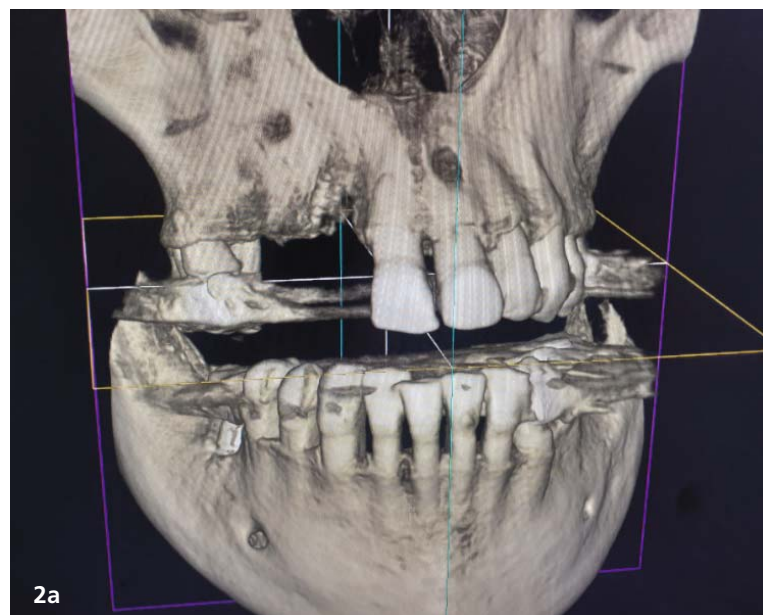


Fig. 2a: Volumetric reconstruction of the female patient denoting partial edentulism of the right posterior maxilla and the need for treatment of the upper left central incisor.

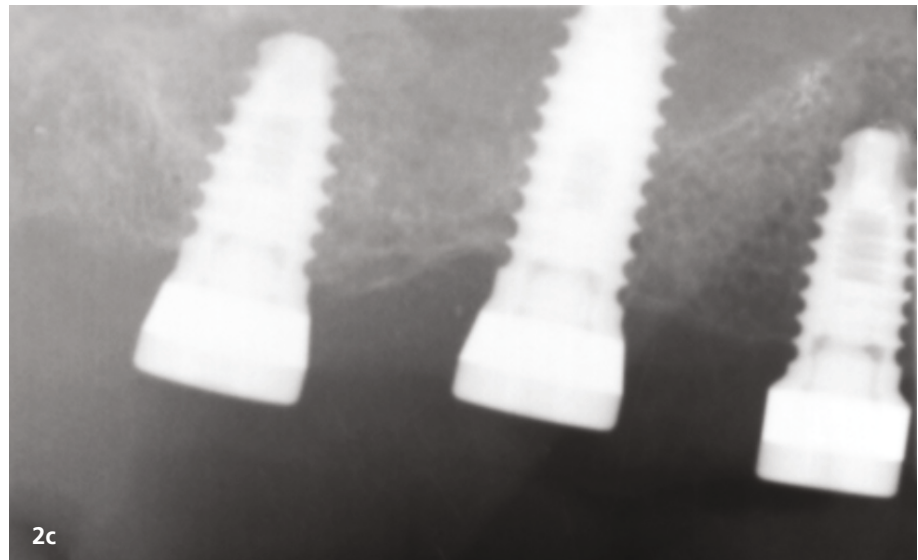
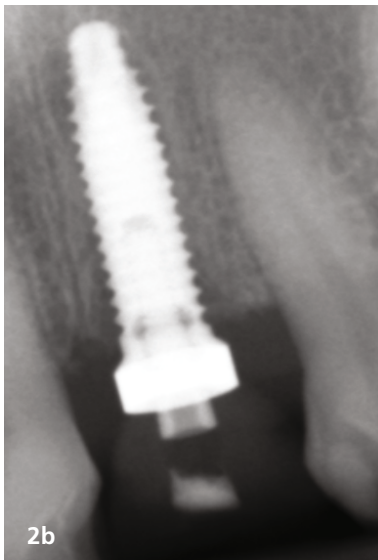


Fig. 2b: Among other rehabilitative options, in accordance with the patient, an immediate implant was placed at the extractive socket of the upper left central incisor. **Fig. 2c:** Among other rehabilitative options, in accordance with the patient, three implants were placed in the edentulous ridge distal to the right upper central incisor.

was used for all surgeries. Teeth were extracted carefully in order to preserve the integrity of the socket walls and to avoid having to raise a flap. In particular, the surgeon took advantage of the existing cleavage spaces, making use of a magnetostriuctive handpiece. After tooth extraction, the surgeon mapped the extraction socket with a #15 UNC periodontal probe and recorded the buccolingual and the mesiodistal diameters. Neither post-extraction fenestrations nor dehiscence were found. Thus, there was no need for further grafting of the socket with biomaterials. Implant site preparation was performed slightly palatally with respect to the socket.

Z1 Infinity implants with a 1.5 mm zirconia collar and of varying lengths (10.5–13.0 mm) were used. The surgeon placed the implants leaving the zirconia collar outside the bone margin. The implants were loaded immediately using screw-retained resin provisional prostheses, taking particular care regarding marginal convexity, apico-coronal position and final polishing of the crown (Figs. 1a–f). If the primary stability was not sufficient and the insertion torque was lower than 25 Ncm, a customised healing abutment was fabricated, and Maryland bridges were used for provisional restoration.

Postoperative care

Antibiotic therapy was continued for five days after the surgery. An analgesic and anti-inflammatory regimen was established for the very first three days (600 mg ibuprofen twice a day) and then when required.

Clinical and patient outcome measures

The following clinical parameters were evaluated at the time of implant placement and six months later: distance from the coronal border of the buccal bone to the coronal border of the lingual bone, measured using a standardised periodontal probe placed horizontally through the centre of the implant; and clinical and radiographic parameters, including plaque index, bleeding on probing, probing depth and clinical attachment level. At the time of the definitive prosthesis placement, a further aesthetic evaluation was performed using the pink esthetic score (PES). All the implants were radiographically examined by one of the authors (EG), who was unaware of the treatment procedure, using an OsiriX DICOM viewer (Pixmeo).

The clinical success of the implants was recorded as the primary outcome of this study. Based on both clinical and radiographic criteria described by Buser et al., the implants were classified as successful

or unsuccessful.¹⁷ The criteria for implant failure were as follows:

1. persistent patient complaints;
2. peri-implant suppurative infection;
3. fixture mobility; and
4. worsening radiolucency at the marginal bone level.

The secondary outcome was the PES, described by Fürhauser et al. in 2005 for the evaluation of implant aesthetics.¹⁸ On the basis of clinical images, seven variables were evaluated and scored by three evaluators in relation to those of a natural reference tooth: mesial papilla, distal papilla, soft-tissue level, soft-tissue contour, alveolar process deficiency, and soft-tissue colour and texture. Using a 0-1-2 scoring system, 0 being the lowest and 2 being the highest value, the maximum achievable PES was 14. Each observer was requested to make two assessments at an interval of four weeks. At the second assessment, the photographs were scored in the reverse order. Digital single-lens reflex camera systems were utilised to capture intra-oral clinical images of patients at each recall visit. To facilitate PES scoring, both the implant study site and the adjacent (premolar sites) or contralateral natural teeth (anterior sites) and their respective mucosa were captured in the digital images. Clinicians recorded photo-

graphic settings for each patient at the initial visit and repeated the identical photographic settings at later visits to standardise image rendering.

Data analysis

The data was entered and proofed for errors. Descriptive and inferential analysis were performed using R (Version 4.0.4; developer). Assessment of evaluator reliability was completed using the intra-class correlation coefficient to analyse both intra-observer agreement (e.g. PES scores assigned for identical images by the same evaluator at different time points) and inter-observer agreement (e.g. PES scores assigned for identical images by two evaluators). The F1-LD-F1 design from the nparLD package was used to time effects on both primary and secondary outcomes. Significance was set at < 0.05 ($p < 0.05$) for all analyses.

Results

All dental implants were placed at the same time as the extraction of failing maxillary teeth. Overall, 20 implants were placed in the inter-premolar area. Extraction sockets eventually presented slight bone loss.

Implant follow-up

At the conclusion of the one-year follow-up, no implants had failed, providing a cumulative survival rate of 100%. There were no signs or symptoms of peri-implant inflammation, and no signs of significant radiographic marginal bone loss could be detected until the last visit.

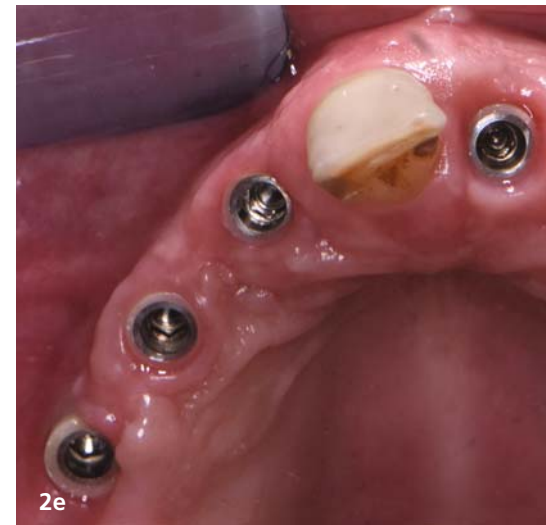
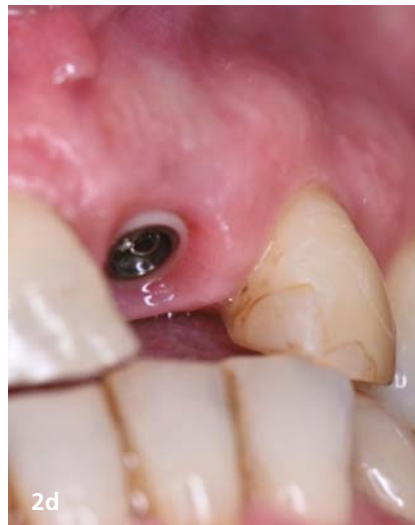
Fig. 2d: Clinical detail of soft tissues. **Fig. 2e:** Clinical detail of soft tissues. **Fig. 2f:** Overall appearance one year after surgery.

PES measures

For the ten patients, the highest and lowest PES values were 14 and 10, respectively. The median PES was 13.5, and 97% of the scores were within the range of 13–14 (Fig. 3). No patients scored a maximum PES of lower than 10 in PES evaluation. The highest PES values were observed for the soft-tissue level (2.00 ± 0.05) and soft-tissue colour (2.00 ± 0.05). The distal papilla (1.75 ± 0.46) and the alveolar process (1.75 ± 0.46) had the lowest scores. The mesial papilla, soft-tissue colour and soft-tissue contour scores were 1.87 ± 0.35 , 1.87 ± 0.35 and 1.87 ± 0.45 , respectively.

Discussion

The present case series suggests that titanium implants with a zirconia collar might be a safe alternative for the rehabi-

litation of partial edentulism in the case of immediate implant placement in the aesthetic zone. The one-year evaluation showed a PES range of 10–14, 13.5 being the median value. No failure or complication could be recorded. No signs or symptoms of peri-implant mucositis were detected. The recent systematic review by Francisco et al., including 18 trials, concluded that both immediate and early implant placement protocols presented stable treatment results in terms of aesthetic outcomes at the one-, two- and ten-year follow-ups.¹⁹ Of course, the placement of implants in extraction sockets comes with several immediate challenges; thus, choosing the right implant, among others, is a determining factor for success.^{20, 21}

In the present study, the implant zirconia neck may have behaved like a bioactive scaffold for the connective tissue to grow on to. This is an advantage because a thick, well-represented, firmly seated connective tissue seal guarantees long-term vertical stability.^{22, 23} Zirconia has been associated with greater fibroblast adhesion, proliferation and viability.^{24, 25} Fibroblasts play a crucial role in the early healing of peri-implant soft tissue, especially in the case of immediate placement of implants, for which several factors come into play, and the healing potential of the surgical injury is influenced by both

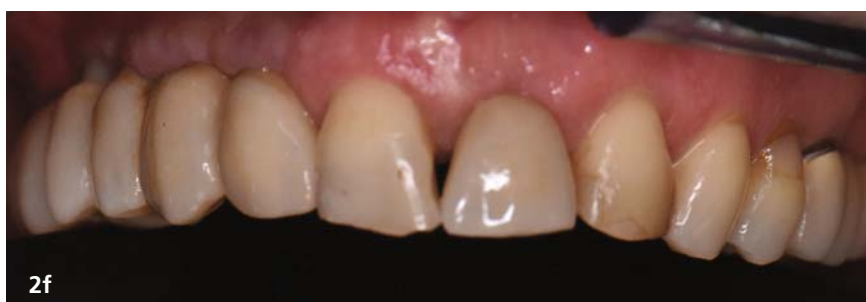

Fig. 2f: Overall appearance one year after surgery.

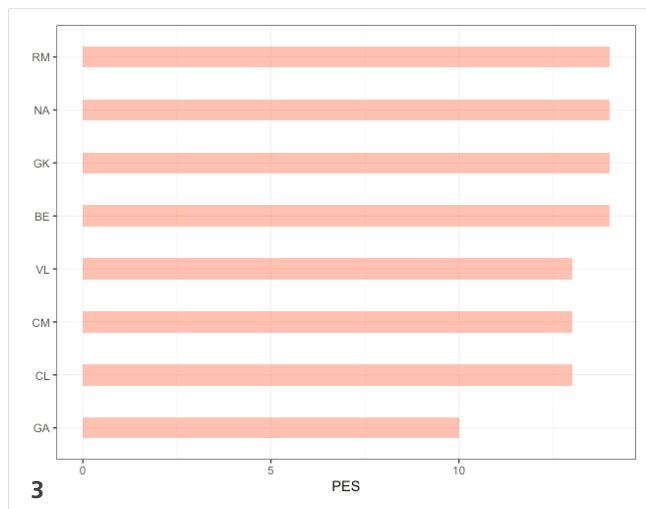


Fig. 3: Average (central incisors, lateral incisors, canines and premolars) pink esthetic score (PES) for each patient of the cohort.

wound size and local tissue resources.²⁶ Wound healing around implants placed immediately starts during the surgery by protein adsorption on the implant or abutment surface, followed by the formation of a blood clot; thus, choosing an implant with a fibroblast-friendly surface at the neck area might aid early soft-tissue stabilisation.²⁷

The results of the present study are in line with those of clinical studies regarding zirconia in implant dentistry: zirconia implants and abutments have been associated with low gingival and plaque index scores.^{28,29} This apparent lower affinity to plaque accumulation may favour soft-tissue health and decrease the long-term risk of inflammation or infection.

The recent network meta-analysis by Hu et al. reported that zirconia abutments had a comparable survival rate to that of titanium abutments.³⁰ In addition, zirconia abutments have a better effect in maintaining the marginal bone level. The authors concluded that zirconia might be a recommended abutment material considering the clinical efficacy of implant-supported single crowns for which zirconia abutments were employed.

The overall mean PES for the present study was 13.5, a value which is consistent with the current literature on zirconia implants and abutments. A recent systematic review of the mechanical and aesthetic outcomes of implant zirconia abutments used in the anterior region reported “good to excellent” aesthetic integration in terms of prostheses and soft-tissue colour and the presence and height of papillae.³¹

Among the limitations of the present study are the absence of a control group and the short follow-up period. Larger studies with control groups and longer follow-ups are needed to assess the long-term stability of Z1 Infinity implants.

About...



Dr Simone Marconcini

has a PhD in nanotechnology from the University of Genoa in Italy, an MSc in bone reconstruction and a national scientific qualification as associate professor in stomatology with experience in teaching at the University of Pisa in Italy in graduate and postgraduate courses. An award-winning specialist in oral surgery and implantology (University of Pisa) with over ten years' experience of research in oral health, he oversees scientific research at the Istituto Stomatologico Toscano, a foundation for clinical research and advanced training in dentistry in Camaiore in Italy. He is a recipient of the IADR/Philips Oral Healthcare Young Investigator Research Grant. He is the author of more than 50 scientific publications in high-impact scientific journals, the co-author of three books and an active member of the International Association for Dental Research and Italian Academy of Osseointegration.

Literature



Contact address


Dr Simone Marconcini

+39 050 5205527

simosurg@gmail.com



The unique Tissue Level Implant with Zirconia Collar



Aesthetic gingival area

Zirconia collar

& Gingival integration
Osseointegration

Bone area

Pure Titanium body



Find us online
www.tbr.dental

Z for Zirconia, 1 for One-stage surgery.