

Extraction, tissue management and implant surgery over the long term

Dr Philippe Jourdan, France

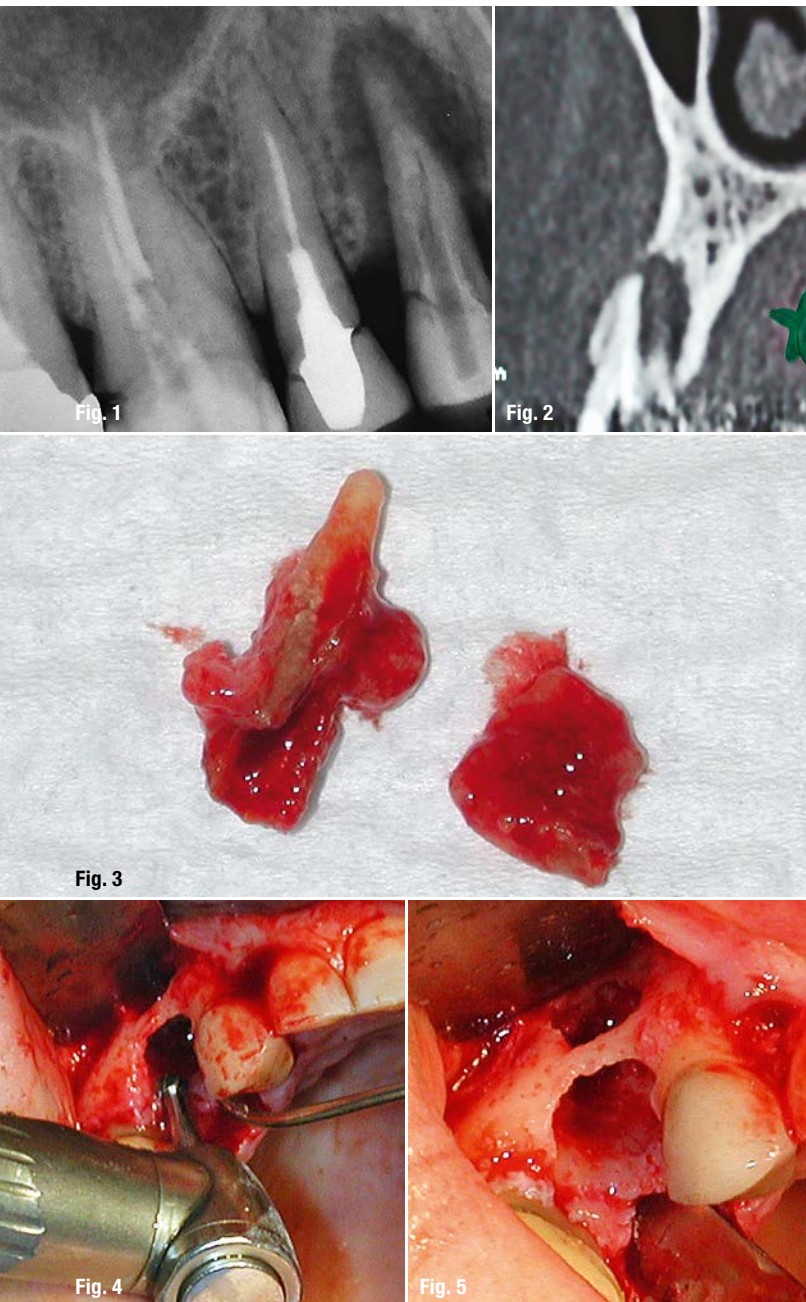


Fig. 1: Pre-op radiograph showing a fractured root. **Fig. 2:** A cyst had developed around the fractured tooth. **Fig. 3:** The extracted tooth in two pieces. **Fig. 4:** Preparation of the surgical site. **Fig. 5:** The cavity after extraction of the tooth.

In this case report, I discuss a successful extraction and implant surgery in a female patient, with no complications after ten years of follow-up.

Assessment

The patient, aged around 60 years, presented with a fractured root of her maxillary right premolar (Fig. 1). A long-time patient of the practice, she was otherwise in a good state of oral health. After an initial assessment, it was discovered that a cyst had developed around the fractured tooth and the serious infection necessitated surgical extraction (Fig. 2). The patient was advised of the options open to her—either a bridge or an implant—and the benefits and potential drawbacks of both. After consideration, she chose the latter and the treatment could proceed.

Extraction

The extraction was a smooth, unhindered process. Owing to its fractured state, the tooth came out in two pieces (Fig. 3). Care was taken to maintain the small bridge of bone on the buccal side (Fig. 4); this would serve as a vital scaffold for the implant, for the bone substitute and for microvascularisation at the site (Fig. 5). Surgery was performed with a flap because of the need for greater visibility owing to the presence of advanced granulation.

Preparation

After the extraction, a bur was used to thoroughly clean the cavity except for the crucial remaining bone fragment (Fig. 6). The bur was used to prepare the fenestration site, with the cavity on the buccal side of the bone. The bur was used for drilling purposes for the preparation of the implant site because piezoelectric technology was not available at the time.

Implant placement

The Z1 implant (TBR Dental) was chosen because of its excellent periodontal integration and suitability for immediate implantation (Figs. 7 & 8). It is specifically designed

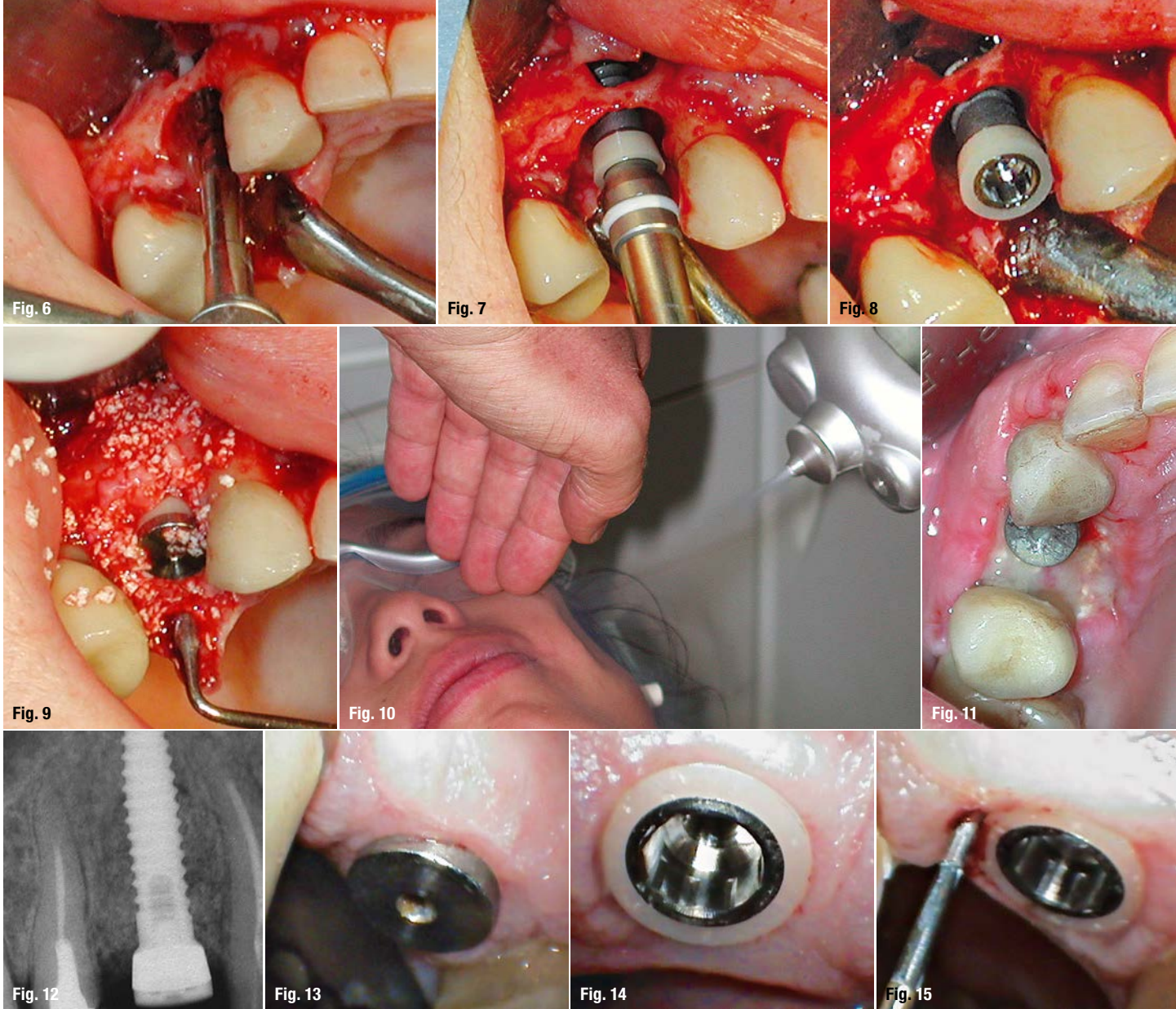


Fig. 6: The cavity was cleaned using a bur. **Figs. 7 & 8:** Placement of the Z1 implant. **Fig. 9:** Platelet-rich fibrin and bone substitute were used as bone grafting material. **Fig. 10:** Cryotherapy was used to prevent inflammation. **Fig. 11:** Occlusal view eight days after surgery. **Fig. 12:** Radiograph eight days after surgery. **Fig. 13:** Situation five months after surgery. **Fig. 14:** The cover screw was removed. **Fig. 15:** Epithelial healing had been successful.

to suit the anatomy of every patient. It is the only tissue level implant which adapts selected materials—zirconia and titanium—to the surrounding tissue. The socket required a graft of platelet-rich fibrin and bone substitute (Fig. 9), to ensure efficient and safe healing of the tissue around the implant. Despite the trauma around the placement site, there was sufficient primary stability to ensure later osseointegration. One-third of the implant had good apical stability, which, in this case, was acceptable. Cryotherapy was then used to prevent inflammation and oedema (Fig. 10). The operation, with no unexpected developments or complications, lasted an hour. Antibiotics were prescribed postoperatively owing to the pre-existing severe infection at the implant site.

Healing period

The healing process was non-problematic, and healing was evident eight days after surgery despite the inflamed appearance (Figs. 11 & 12). Five months later, the osseo-

integration and gingival integration process had also been successful (Fig. 13), a highly pleasing result considering the severe trauma to the bone. The cover screw was removed (Fig. 14), and the space between the zirconia collar and the tissue was probed to determine the status of the periodontal attachment. Owing to the biocompatibility of the Z1 implant's zirconia collar, effective epithelial healing had taken place (Fig. 15).

Implant restoration

The abutment and the crown were placed (Figs. 16 & 17), and temporary cement applied to the crown for retention. Once again, there were no complications. The appearance of the gingival tissue around the crown showed the desired stippled consistency, displaying a rough texture but without the presence of bleeding or inflammation (Fig. 18). Owing to the employment of an in-practice technician, all postoperative procedures could be performed conveniently and efficiently on-site.

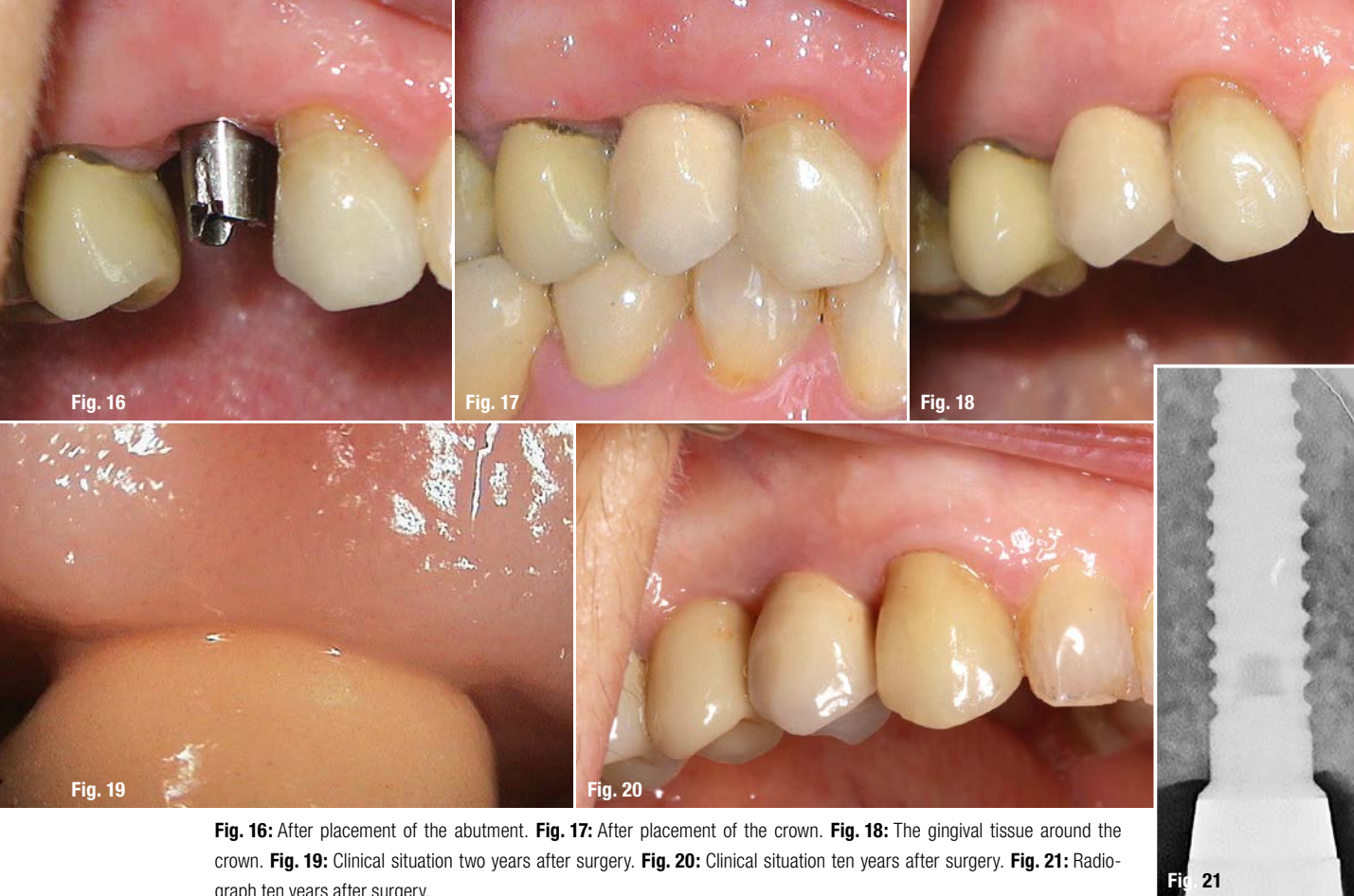

Fig. 16: After placement of the abutment. **Fig. 17:** After placement of the crown. **Fig. 18:** The gingival tissue around the crown. **Fig. 19:** Clinical situation two years after surgery. **Fig. 20:** Clinical situation ten years after surgery. **Fig. 21:** Radiograph ten years after surgery.

Final results

The pleasing results of the implant surgery continued to be seen two years after the operation. Natural papillae had developed around the crown, compared with the flat appearance of the tissue initially (Fig. 19). Dental implants must integrate with the three surrounding tissues: the bone, connective tissue and epithelial tissue. The main challenge involved with the implant's periodontal integration is the long-term stability of the implant-tissue interface. This challenge is met by this tissue level implant with a zirconia collar.

The comparison between a tissue level surgical technique and a bone level surgical technique shows a considerable advantage. In this case, the crown was supported directly on the implant platform. However, if we had opted for a bone level surgical technique, this same crown would have been cemented on to the shoulder of the abutment. The tissue level surgical technique is, therefore, much less invasive for soft tissue. On the one hand, it does not constrain or mobilise the gingival tissue once the implant has been placed, and on the other hand, zirconia has aesthetic and antibacterial properties superior to those of titanium. In this technique, the combination of using a zirconia collar at soft-tissue level and a ceramic crown ensures a ceramoceramic continuity, significantly improving the aesthetics of the restoration.

A full ten years after surgery, there had been no complications and the tissue surrounding the implant remained strong and healthy (Fig. 20). The papillae had continued

to grow healthily around the zirconia collar and the crown. Most importantly, there was no bone cratering (Fig. 21). The patient, aged 70 at the ten-year follow-up, repeated her satisfaction with the surgical procedures and her crown a decade after her initial treatment.

about the author



Dr Philippe Jourdan is a dentist from France specialised in dental surgery. Between 1983 and 1988, he completed several postgraduate training programmes both in Toulouse and Marseille in France. Since 1986, he has been in private practice in Balma in France.

contact

Dr Philippe Jourdan

Balma Dentaire
1 Place France
31130 Balma, France
Phone: +33 5 62576222

www.selarl-balma-dentaire.chirurgiens-dentistes.fr

Author details

