

# Sixteen years of **follow-up** after insertion of a Z1 implant

Dr Virgilio Masini, Italy

**In the following case report** Italy-based oral surgeon Dr Virgilio Masini describes how the advantages of a titanium implant with a zirconia collar can ensure long-lasting function and aesthetics.

In 2003, a 40-year-old female patient presented with a removable prosthesis in the region of tooth #24, which had been extracted the year before owing to a fracture (Fig. 1). Treatment options for restoring region #24 with a fixed solution were discussed with the patient, who wanted a more comfortable alternative to the removable restoration that she had. The patient decided to have a dental implant placed and restored with a metal–ceramic prosthesis in order to avoid damaging the two adjacent teeth. A radiograph was taken to assess whether the pa-

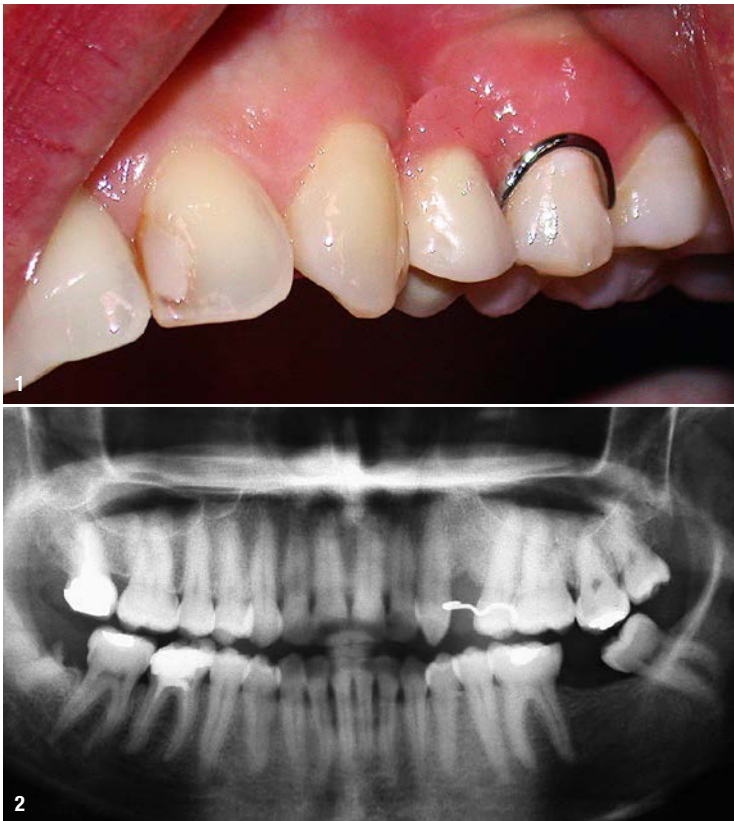tient had adequate width and height of bone for implant placement (Fig. 2). This revealed that, as a result of the fracture of the extracted tooth #24, the patient had lost a large part of the buccal bone plate. The radiograph also showed that the patient had retained the residual root of tooth #48. To ensure sufficient quality and quantity of buccal bone, it was decided that the residual root of tooth #48 would be extracted at the same time as implant placement in region #24, and the bone surrounding the tooth root would be used as part of a guided bone regeneration (GBR) procedure. To maintain the hard and soft tissue more coronally, a 13 x 4 mm Z1 implant (TBR Dental) with a zirconia collar height of 3 mm was planned for.

## Implant placement

The surgical aspect of treatment began with the extraction of the residual root in the region of tooth #48. At the same time, fragments of bone from the surrounding area of the surgical site were extracted and mixed with hydroxyapatite of equine origin. Once the extraction site had been closed and sutured together, a delayed implant placement protocol was followed for region #24. This involved making an incision in the gingiva and raising a flap to expose the buccal bone. The hole was then drilled before the implant was placed successfully at soft-tissue level and a cover screw fitted (Fig. 3). At this point, GBR was performed using the fragments of the bone taken from the surrounding area of tooth #48 (Fig. 4), which were placed on the buccal bone of the implant site and covered with a resorbable collagen membrane (Fig. 5) that was fixated with a micro screw. A radiograph was taken to confirm that the implant was positioned correctly (Fig. 6), and the patient was given appropriate post-surgery care instructions.

## Implant restoration

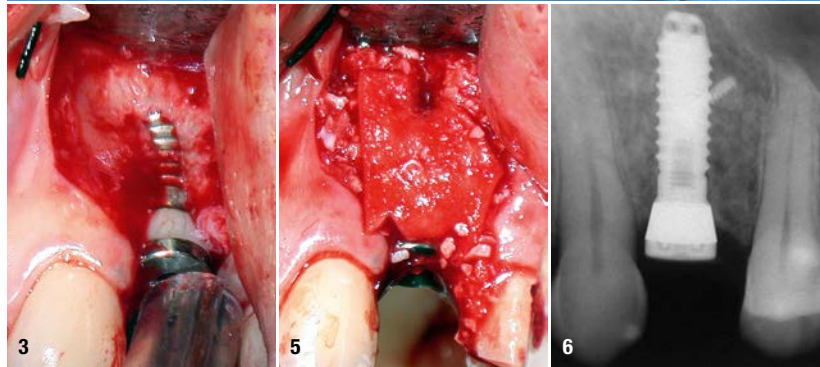
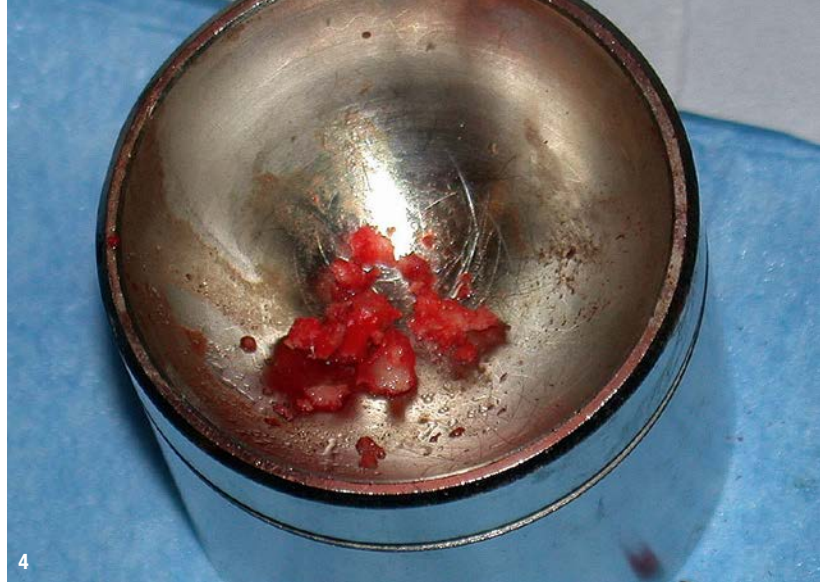Six months after placement, the implant was reviewed and found to be stable. The patient had experienced a slightly prolonged period of post-surgical oedema, but this had been effectively controlled with non-steroidal anti-inflammatory medication. As a result, the soft-tissue was pink and healthy and there were no signs of inflammation (Fig. 7). The implant was restored with a straight



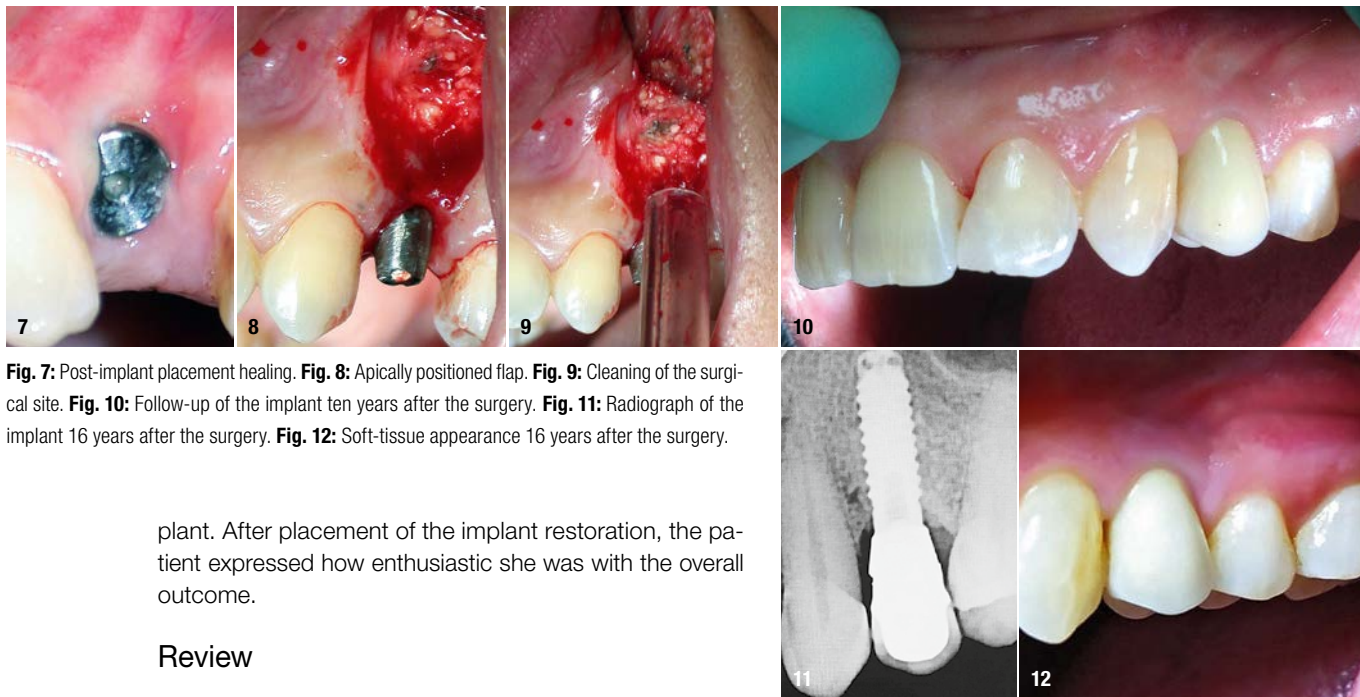
**Fig. 1:** Removable prosthesis in the region of tooth #24. **Fig. 2:** Panoramic radiograph prior to implant surgery.

stock titanium abutment and a metal–ceramic crown. In cases of a classic fixed prosthesis and healed tissue—where the overflow of cement can easily be controlled—I always prefer to use cement-retained restorations, unless the height of the prosthesis is low and there is a risk of de-cementation. It is widely known that excess cement is one of the main causes of peri-implantitis.<sup>1</sup> Screw-retained restorations are my preference for full-arch restorations and cases of immediate loading, even for single crowns.

To further optimise the aesthetic result in this case, the implant was loaded with the final restoration after a soft-tissue management protocol. This was carried out by making an incision and raising an apically positioned flap to increase the amount of attached gingiva at the surgical site (Figs. 8 & 9). At this time, the micro screw was removed and it was confirmed that the GBR procedure had indeed been successful. The surgical site was then sutured together. The soft tissue was effectively managed by the zirconia collar of the Z1 implant and the cover screw, which meant that a temporary restoration was not necessary. A metal–ceramic crown was used in this case owing to my lack of experience with zirconia crowns at the time. However, if this case presented today, a zirconia crown would have been chosen to restore the im-



**Fig. 3:** Implant placed in region #24. **Fig. 4:** Material preparation for the guided bone regeneration. **Fig. 5:** Placement of the guided bone regeneration material. **Fig. 6:** Radiograph of the implant in region #24.



**Fig. 7:** Post-implant placement healing. **Fig. 8:** Apically positioned flap. **Fig. 9:** Cleaning of the surgical site. **Fig. 10:** Follow-up of the implant ten years after the surgery. **Fig. 11:** Radiograph of the implant 16 years after the surgery. **Fig. 12:** Soft-tissue appearance 16 years after the surgery.

plant. After placement of the implant restoration, the patient expressed how enthusiastic she was with the overall outcome.

### Review

During a routine check-up in 2013, the implant was reviewed. The patient was very happy with the final result and remains a regular patient of the practice. The gingiva around the implant was pink and the papilla had also been maintained so that the implant restoration demonstrated aesthetics and function similar to those of the natural teeth (Fig. 10). The zirconia collar of the Z1 implant had encouraged optimal healing of the soft tissue around the implant to create an excellent emergence profile. It also eliminated the risk of the titanium components becoming visible through the gingiva. Sixteen years after the surgery, the implant was reviewed again and the final outcome remained unchanged. A radiograph showed that there was minimal bone resorption and that the implant was stable (Fig. 11). The soft tissue also appeared healthy and there was no difference between the implant restoration and the surrounding natural teeth (Fig. 12).


### Discussion

Prior to implant placement, the patient in this case had experienced bone loss as a result of the fracture of the extracted tooth #24. However, the zirconia collar of the Z1 implant was able to stabilise the soft tissue coronally at the implant site, a result that had improved over time. The benefits of the Z1 implant are mainly aesthetic, as it helps manage the soft tissue and improves plaque control. Indeed, zirconia surfaces demonstrate a lower affinity to bacteria compared with titanium.<sup>2</sup> The Z1 implant system is my implant of choice in cases in which I want to maintain the soft tissue and avoid bone augmentation (for instance, in the case of immediate post-extraction implants with moderate loss of the buccal bone plate). In the molar area of patients who have difficulty controlling plaque, I also prefer to position the implant edge at tis-

sue level or even slightly supragingivally. This case ultimately demonstrates that choosing a top-quality implant solution can help ensure that patients benefit from an outstanding, long-lasting restoration that is highly aesthetic and functional.



### about the author



**Dr Virgilio Masini** graduated in medicine and surgery with honours from the Sapienza University of Rome in Italy in 1982 and specialised in dentistry with honours at the University of Rome Tor Vergata in Italy. He has a special interest in implantology. For three years, Dr Masini attended the Maxillofacial Surgery Complex Operational Unit at the University Cattolica del Sacro Cuore in Rome. Dr Masini has also taught in the master of oral surgery and implantology programme at the Gabriele d'Annunzio University of Chieti–Pescara, University of Naples Federico II, Sapienza University of Rome and Vita-Salute San Raffaele University in Milan.

### contact

**Dr Virgilio Masini**  
Via Piave 7  
00187 Rome, Italy  
Phone: +39 06 8540759  
www.odontoiatriadrmasini.it

